

## INVESTIGATION OF MALE INFERTILITY IN LLAMAS AND ALPACAS

### Investigación de la infertilidad del macho en llamas y alpacas

A. Tibary and A. Ruiz

Comparative  
Theriogenology,  
Department of Veterinary  
Clinical Sciences,  
Washington State  
University College of  
Veterinary Medicine,  
Pullman, USA

\* Corresponding author

Address:  
Washington State  
University College of  
Veterinary Medicine,  
Pullman, WA 99164 USA

E-mail: [tibary@wsu.edu](mailto:tibary@wsu.edu)

#### ABSTRACT

Reports on causes of infertility and subfertility in male llamas and alpacas are lacking. The aim of the present paper is to present a review of the literature and an approach to breeding soundness examination of the male in these species. Results from a retrospective evaluation of breeding soundness evaluation of males intended for use as sires (N= 202) and those presented for complaint of infertility/subfertility (N= 71) are presented. Testicular hypoplasia, testicular degeneration and cystic condition of the testis were the most common findings in infertile males. In our practice, ejaculates obtained by postcoital aspiration or electroejaculation show a higher rate of sperm abnormalities than reported by others. A need for standardized breeding soundness examination guidelines is discussed.

**Keywords:** Semen, reproduction, libido, Pathology, impotencia

#### RESUMEN

Reportes sobre las causas de infertilidad y subfertilidad en llamas y alpacas macho son escasos. El objetivo del presente trabajo es presentar una revisión de la literatura y un criterio sólido para el examen reproductivo del macho en estas especies. Aquí presentamos los resultados de una evaluación retrospectiva de la evaluación reproductiva de los machos destinados a ser utilizados como reproductores (N = 202) y aquellos que presentaron problemas de infertilidad / subfertilidad (N = 71). La hipoplasia testicular, la degeneración testicular y el estado quístico del testículo fueron los hallazgos más comunes en machos infértiles. En nuestra práctica, los eyaculados obtenidos por aspiración postcoital o electroeyaculación muestran una mayor tasa de anomalías espermáticas que las reportadas por otros. Además, discutimos la necesidad de criterios estandarizados para el examen reproductivo del macho.

**Palabras clave:** Semen, reproducción, libido, Patología, impotencia

## INTRODUCCION

Unlike the cattle and sheep industries, there are no standards for male breeding soundness examination classifications in camelids. Some guidelines have been cited in the literature as to minimum requirements for testicular size and ejaculate characteristics (Pearson et al., 2014). In several countries outside South America, many males are mated to a few females and produce offspring despite observed abnormalities in testes size or semen quality. Traditionally, males are used in a multi-sire system which tends to confuse the issue of male fertility. In well managed herd, a pregnancy rate of 80% or more is expected with mature males in a breeding season of 90 days (Condorena and Velasco, 1978). Furthermore, males are often selected as a herd sire based on pedigree, fiber quality, conformation, or show performance, and not on reproductive parameters. Observed male fertility is also affected by herd health and fertility of the females as well as the length of the breeding season. Studies on male fertility in a production system are lacking in this species and reports on reproductive disorders in the male are limited to single case reports. To our knowledge the only detailed descriptive study on reproductive disorders performed on a large number of animals is that reported by Sumar in 1983 (Sumar, 1983, 2013). In that study, 18.1% of 544 males that underwent clinical evaluation had a testicular pathology. In the same study, 30.5% of 242 males examined postmortem (slaughterhouse specimen) showed a testicular disorder (Sumar, 1983). This relatively high incidence of genital disorders emphasises the need of warrants a complete breeding soundness examination for prepurchase or selection of prospective sires.

During the past 20 years, the comparative theriogenology service at WSU has served as a referral center for alpaca and llama (here referred to as South American Camelid or SAC) infertility. This objective of this paper is to discuss our approach to breeding soundness examination in the male camelid both for the prospective sires as well as for male presented for infertility. Some of the data presented here have been discussed by the authors previously (Campbell and Tibary, 2017; Tibary et al., 2014; Tibary and Campbell, 2016).

## Applied reproductive anatomy and physiology

Reproductive physiology of male SAC has been discussed at length in several publications (Bravo, 2014; Tibary and Vaughan, 2006). In brief, the male SAC should have two descended scrotal testes at birth. Prepuberal development is accompanied by increasing androgen production. The increase in testosterone production is accompanied by mounting activity and freeing of the penis from its preputial attachment (Oscanoa M et al., 2017). This process usually begins at 12-13 months in alpacas and up to 20 months in llamas. Only 10% of males are able to exteriorize the penis at one year of age. By 2 years of age about 70% of males have lost preputial adhesions. All males should be able to fully exteriorize the penis by 3 years of age. In a recent study in the authors' laboratory, 85% of males had observation of preputial detachment by 18 months of age (El Zawam, 2013). This wide variation in detachment of penile-preputial adhesions may be due to genetic differences, nutrition, and proximity to other males and females.

Testicular growth and spermatogenesis have been partially studied (Delhon and Lawzewitsch, 1987; Delhon and Lawzewitsch, 1994; El Zawam, 2013). Mean testicular size and weight has been reported for different ages (Table 1). In a recent study on alpacas, testicular length was found to be a good predictor for sperm production. Males with testicular length equal or greater than 3.8 cm would be producing sperm (Abraham et al., 2016). Male SAC appears to reach sexual maturity at 4 to 5 years of age. Histologically, the SAC camelid testis is organized similarly to that of other domestic animal species. Seminiferous tubules diameters increase in size with increasing age and a lumen appears with full spermatogenesis. Spermatozoa appear in the lumen of the seminiferous tubules between 15 and 24 months of age. However, some males may reach this stage earlier (10 to 12 months) (El Zawam, 2013). Spermatogenesis is similar to that describe for other species (Delhon and Lawzewitsch, 1987; Tibary and Vaughan, 2006). To our knowledge studies on the length of the spermatogenic cycle and duration of spermatogenesis are lacking. Seasonal variation in sperm production and quality has been observed and is likely due to climatic conditions (temperature and humidity) as well as nutrition (Huanca et al., 2011; Tibary et al., 2014; Schwalm, 2007).

**Table 1.** Mean testicular length x width (cm) and weight (g) in alpacas and llamas at different ages (adapted from (Sumar, 1983; Bravo, 2002)).

Age (months)	Alpaca (n=158)		Llama (n=54)	
	Size (cm)	Weight (g)	Size (cm)	Weight (g)
6	1.0 x 0.4	0.6	2.4 x 1.4	-
12	2.3 x 1.5	2.9	3.4 x 2.3	5.1
18	2.8 x 1.9	6.6	3.5 x 2.6	14
24	3.3 x 2.2	9.9	3.9 x 2.3	17.4
30	3.6 x 2.3	13.9	4.4 x 2.5	17.8
36	3.6 x 2.4	13.6	4.5 x 2.7	18.2
Sires	3.7 x 2.4	17.2	5.4 x 3.3	-
Sires (Sumar, 1983)	4.0 x 2.6	17.7		

Camelid mating behavior presents several peculiarities. Males display flehmen response following investigation of the female vulva, urine or feces (Figure 1). They elevate their head and lift the upper lip without curling it while the mouth is slightly open. Mating takes place with the female in sternal position. The male mounts the female and assumes mating position with the hocks

completely flexed and the metatarsi on the ground. This position can be extremely strenuous on older males and males with osteoarticular disorders (Pearson et al., 2014). Copulation last between 12 and 25 minutes and sometimes even longer. Factors affecting copulation length include age of male and female, individual sire, season, frequency of use and

presence of other males (see reviews (Bravo, 2014; Tibary and Vaughan, 2006). Ejaculation occurs throughout most of the copulatory period during which urethral pulses occur in clusters at regular intervals separated by repositioning (Lichtenwalner et al., 1996a). Studies on llamas have shown that ejaculation start about 4 minutes after initiation of copulation and occurs every minute. Semen is deposited deep in the uterine horn onto the papilla of the utero-tubal junction. The deposition of semen (i.e seminal plasma) and mechanical irritation of the endometrium during mating is responsible for induction of ovulation. The seminal factor involved in ovulation has been identified as  $\beta$ -Nerve Growth Factor (Adams et al., 2016; Kershaw-Young et al., 2012;). Bulbourethral gland secretion are responsible for the viscous nature of the ejaculate and are very important in the formation of the oviduct sperm reservoir and preparation for fertilization (Apichela et al., 2014).



**Figure 1.** Flehmen response in an alpaca.

## BREEDING SOUNDNESS EVALUATION

As a general rule all prospective herd sires should undergo a complete breeding soundness examination (BSE) prior to use around 2 years of age. This examination aims to determine the ability of the male to produce and deliver spermatozoa (normal spermatogenesis, sperm transport, and mating behavior). Some young males may show signs of immaturity (poor sperm quality and quantity). A final decision on the breeding ability of the male is usually achieved at 3 years of age. We also recommend male BSE on an annual basis and in any situation where pregnancy rate are below normal. This examination should include history, general physical exam, testicular examination and measurement, observation of mating behavior and semen collection and evaluation (Pearson et al., 2014; Tibary et al., 2014).

### History

Any male camelid which presents for reproductive examination should be accompanied by a detailed health and reproductive history, including all previous examinations of testicular size, ultrasonography, and semen evaluation. Unfortunately, in many cases, the first examination of a male is performed only when a problem exists, whether physically visible (such as penile or scrotal injury) or due to poor reproductive performance.

Breeding records are extremely valuable. Ideally a database should be available with ID of bred females, date and duration of breeding, and outcome of mating (establishment of pregnancy). Increased observation of interrupted breeding

should be noted. Unfortunately such information is only available under some breeding management scheme (single sire mating group or in-hand mating). In a large population, multiple sires are used which often masks any male problems. Advances in parentage verification can be helpful in identification for infertile or subfertile male. Travel history should be included, particularly to shows or other breeding farms where contact with sick animals may have occurred. General health history should include episodes of fever, skin lesions, lameness, colic, or injuries. Nutritional history should include the type of feed (hay, concentrates, pasture access), and any hay or trace mineral analysis, if previously performed (Pearson et al., 2014).

For specific complaints regarding the reproductive tract, the duration and severity should be noted. For example, acute onset of scrotal enlargement should be differentiated from chronic. For penile injuries due to masturbation, the frequency, duration, and objects bred should be recorded. For decreased libido or difficulty completing the breeding, a time-frame and associated other events (travel, injury) should be noted (Tibary and Campbell, 2016).

### Clinical examination

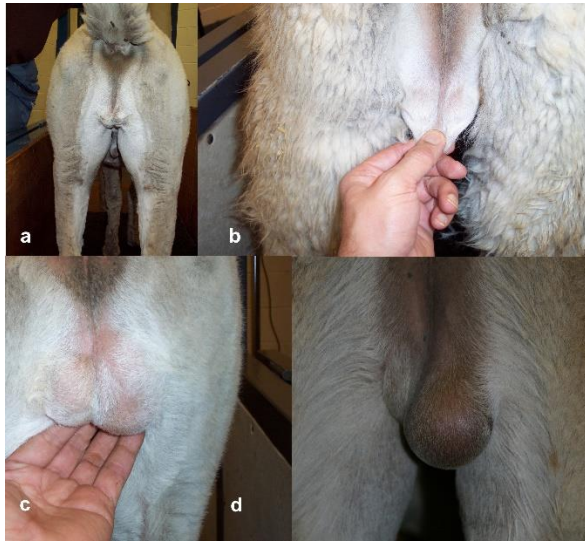
Clinical examination begins with general inspection of the animal. Any systemic disorders should be investigated (enlarged lymph nodes, heart murmur, etc.). Any significant cardiovascular, musculoskeletal, or visceral defects should remove the animal from breeding consideration due to the unknown heritability of most defects in these species (Sumar, 1989; Tibary et al., 2011; Vaughan et al., 2000). It is important to emphasize body condition score of the animal examined as it has been linked to variation in testicular size and sperm production ability (Abraham et al., 2016). Introduction of new superior breeding males is one of the most important aspect of herd improvement. However, it constitutes a breach in herd biosecurity. Therefore, strict measures should be taken to avoid introduction of contagious diseases. Disease testing and quarantine time depends on regional disease prevalence and monitoring system.

Reproductive evaluation begins with the evaluation of the external genitalia. Both testes should be present in the scrotum. The scrotum is non-pendulous but may appear so in older males or animals which have experienced testicular degeneration. The testes are nearly equal in size and may be slightly offset. The skin of the scrotum should be examined for punctures, lacerations, or dermatitis (Figures 2-5). On palpation, the testis should be freely movable, smooth, non-painful and resilient. The tail of the epididymis may be palpated as a small firm structure (Figure 6). The length and width of each testicles should be measured with calipers or ultrasonography (Figure 7). Testicular ultrasonography is an important step in the evaluation of breeding males. The technique is described in detail by the authors elsewhere (Tibary and Ruiz, 2018b). The testicular parenchyma should be homogenous, and the mediastinum testis should be echogenic (Figure 8).

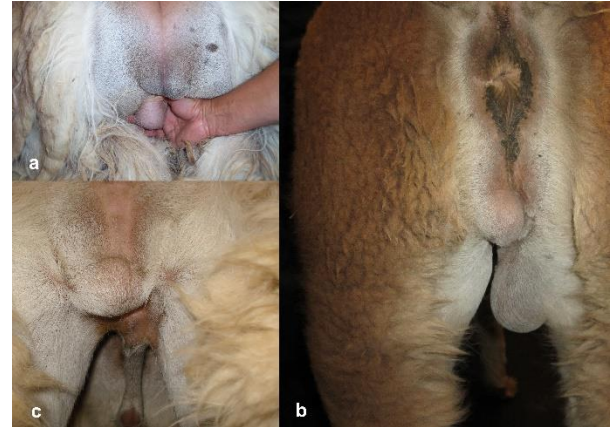
The prepuce should be normal. The penis is briefly examined during a mating trial (Figure 9). Detailed examination of the penis is usually performed under general anesthesia if warranted (i.e. failure of erection or partial exteriorization of the penis. The glans is inspected for any lesions, including pustules, lacerations, hair-rings, or abrasions. Inability to exteriorize the penis in an adult male should raise suspicion of adhesions or persistent frenulum (Pearson et al., 2014). Some males may present dysuria or stranguira. Urolithiasis is a



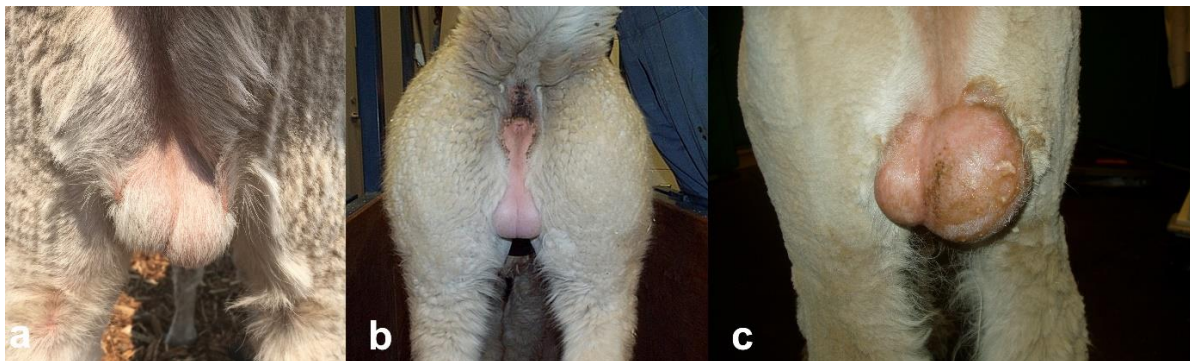
common finding. In pubertal animals the prostate may enlarge under testosterone influence resulting in transient stranguria.



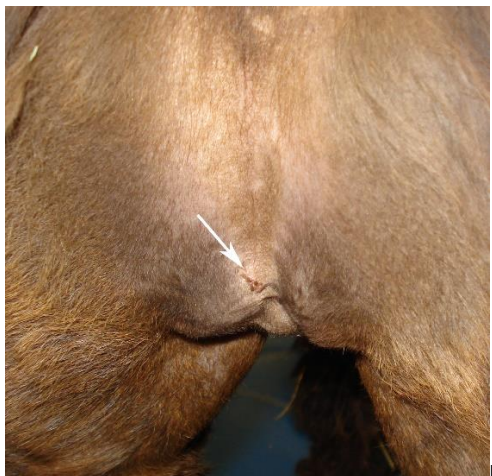
**Figure 2.** Scrotal testicular examination: Testicular degeneration; a)- bilateral testicular degeneration in a 7 year old alpacas, b) bilateral testicular degeneration, note the excessive scrotal kin, c) testicular asymmetry due to unilateral testicular degeneration, d) severe unilateral testicular degeneration due to an orchitis.



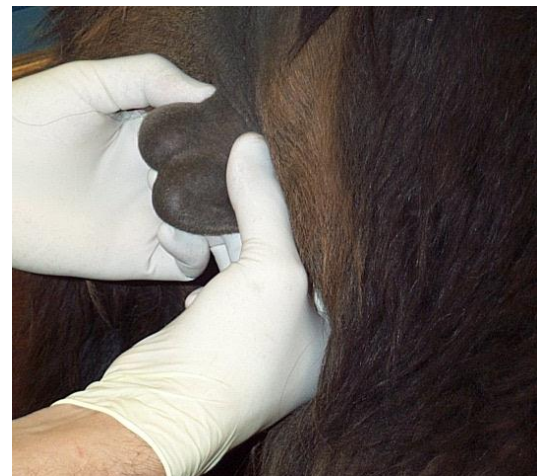**Figure 3.** Scrotal/testicular examination: Congenital defects; a- b) ectopic testicles, c) unilateral right cryptorchidism.



**Figure 4.** Scrotal/testicular enlargement: Scrotal edema (a) and hydrocele (b) due to heat stress, c) unilateral enlargement due to neoplasia (courtesy Dr. Richardson)

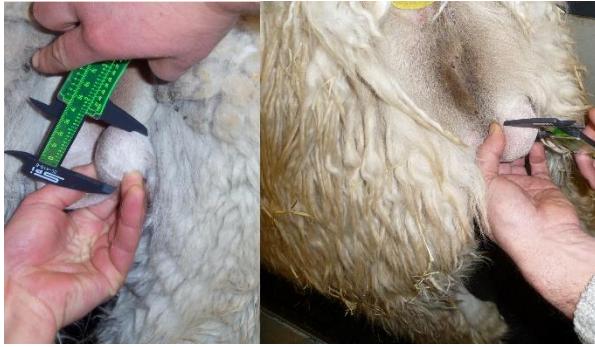

**Figure 5.** Scrotal skin lesion due to a bite

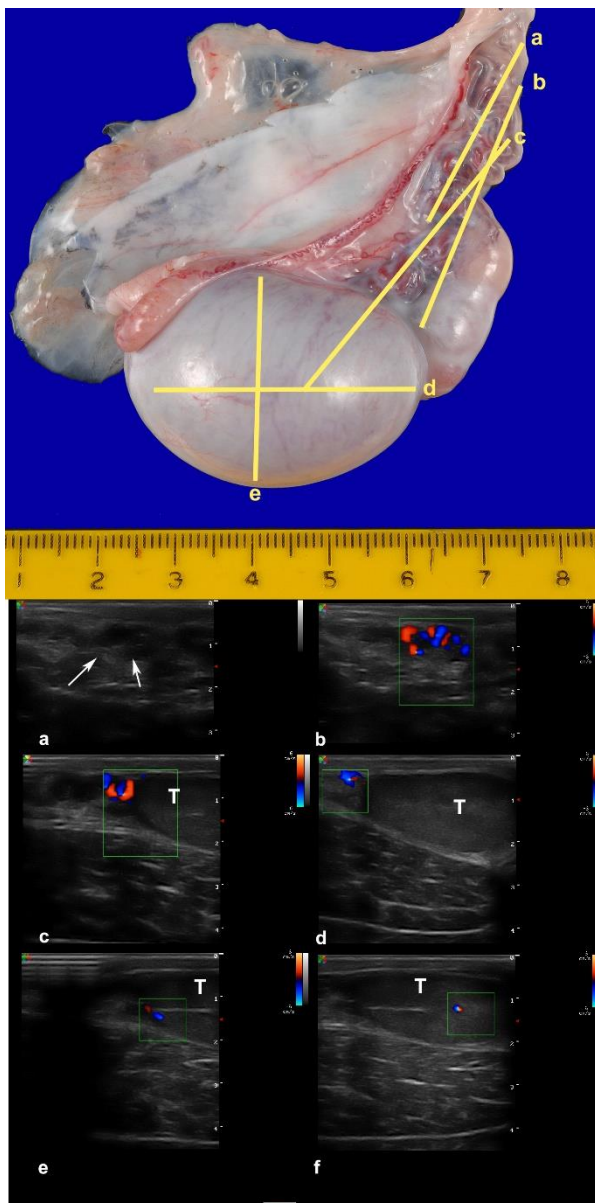


**Figure 6.** Testicular palpation

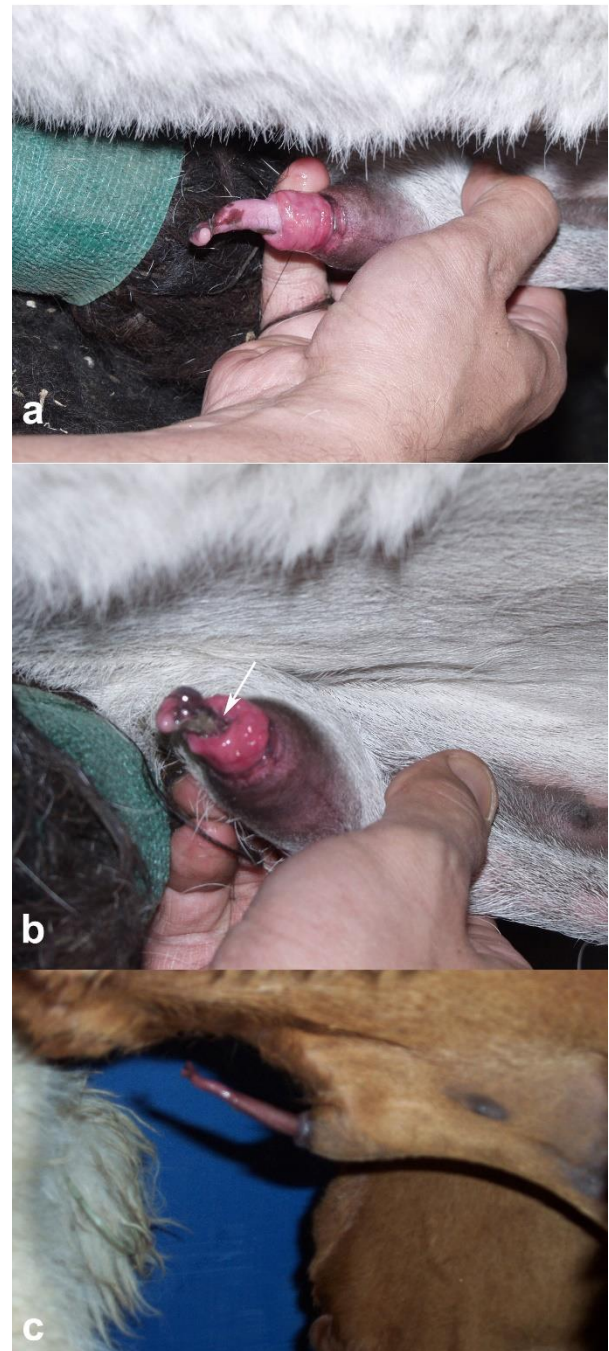




**Figure 7.** Testicular measurements: length x width

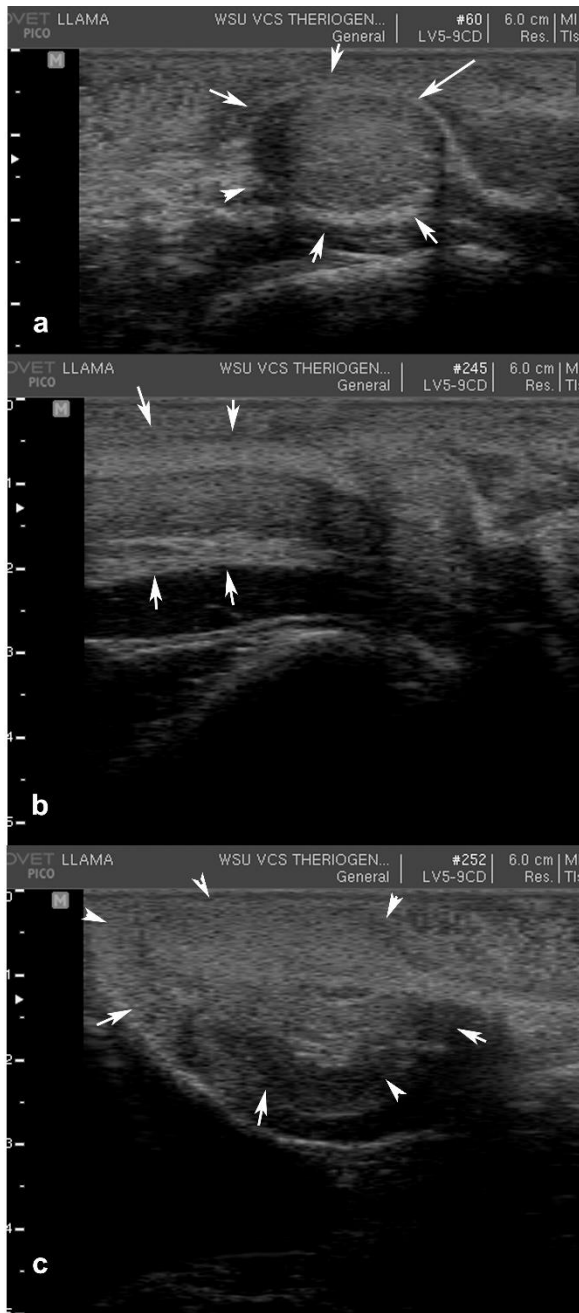

**Figure 8.** Ultrasonogram of the spermatic cord. a) Without Doppler, the testicular artery appears anechoic, b-c) Doppler ultrasonography of the testicular artery as it courses toward the testicle (T), d) dorsal branch of the testicular artery at the level of the caput epididymis, e) ventral branch of the testicular artery, f) Doppler showing testicular perfusion



**Figure 9.** Examination of the penis during mating: a-b) Phimosis due to posthitis, note the presence of debris inside the prepuce (arrow). C) abnormal erection, note the curvature of the penis (arrow)

Examination of the internal genitalia may be required, usually in preparation for electroejaculation. Camelids lack seminal vesicles (Mendoza et al., 2012; Tibary et al., 2014). The prostate and bulbourethral glands are examined for size and presence of any lesions (Sánchez and Correa, 1995; Pearson et al., 2014) (Figure 7). The distance from the prostate to the anus is measured to assist in proper placement of the electrodes during semen collection (Giuliano et al., 2008; Pearson et al., 2013) (Figure 10).



**Figure 10.** Ultrasonographic examination of the accessory sex glands: a) bulbourethral gland, b) pelvic penis/urethra, c) prostate

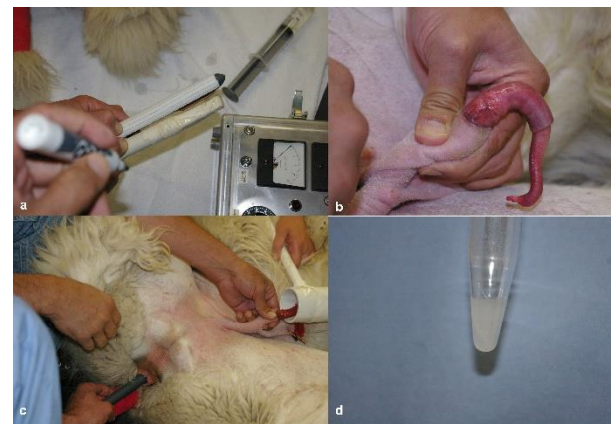### Semen collection

Several methods have been used successful for the collection of semen in SAC. They include the use of various types of artificial vaginas, electroejaculation, post-coital aspiration from a mated female, and post-coital collection with a condom or sponge (Pacheco Curie, 2008; Giuliano, S., 2012; Tibary et al., 2014). In our clinic, we use the post-coital aspiration as a screening method and submit all subfertile males to electroejaculation. Semen collection and evaluation should be performed after at least 2 and preferable 5 days of sexual rest.

Several artificial vaginal semen collection methods have been described, they differ mainly in the design of the artificial

vagina and whether it is mounted on a dummy or used with a receptive female. The temperature and pressure of the artificial vagina should be maintained constant due to the length of the mating. This technique requires some training of the male but produces repeatable results. The main issues with this technique of semen collection are the increased frothing of the ejaculate, risk of contamination and the toxicity of some of the rubbers used as liners (Alarcón B et al., 2012; Bravo et al., 1997a; Bravo et al., 1997b; Evangelista-Vargas et al., 2017; Ferré et al., 2015; Flores et al., 2002; Giuliano et al., 2008; Lichtenwalner et al., 1996b; Morton et al., 2010). It is important to note that during training, some males may produce only seminal plasma without spermatozoa in some ejaculates. Males with high libido and larger testicles seem to accept the artificial vaginal and ejaculate more readily than males with poor libido (Muchotrigo et al., 2013).

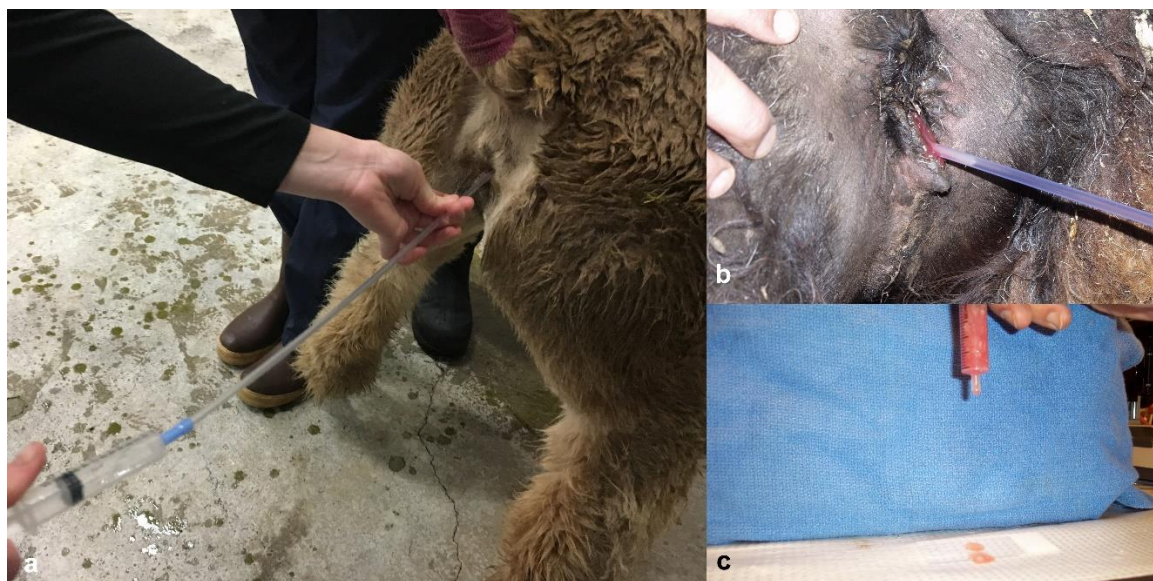
Electroejaculation (EE) presents the advantage of collection of clean ejaculate. This technique is most successful if the male is allowed first to void urine and empty the urinary bladder (Giuliano et al., 2008). The animal is placed under general anesthesia. Our standard protocol used intramuscular injection of a combination of Ketamine (3-4 mg/kg), butorphanol (0.03-0.04 mg/kg) and xylazine (0.3 to 0.4 mg/kg in lateral recumbency (Pearson et al., 2014). An electroejaculation probe with linear electrodes is placed over the prostate, at the distance measured ultrasonographically earlier in the examination (Giuliano et al., 2008; Pearson et al., 2013). The penis is exteriorized and held manually with a collection tube (Figure 11). Electrical stimulation is applied starting at very low voltage. Despite general anesthesia, electrical stimulation will result in hind limb movement and muscle contraction. In a series of studies performed in the author's laboratory, EE was shown not to incite a higher stress response than anesthesia alone (Picha et al., 2011).



**Figure 11.** Semen collection by electroejaculation under general anesthesia. A) the distance from the anus to the prostate is measured by ultrasonography, b) the penis is exteriorized, the electrodes are placed at the level of the prostate, d) the ejaculate obtained is usually clean

For post-coital semen collection, the male is mated to a receptive female and semen aspirated from the female tract using a sterile insemination pipette blindly or through a vaginoscope (Figure 12). This method of semen collection has the advantage of ease and allows evaluation of the male's libido, erection and physical ability to mate. However, aspirated semen is typically contaminated with erythrocytes and/or leukocytes from the female tract (Figure 10) (Alarcón et al., 2012; Pearson et al., 2013).





**Figure 12.** Semen collection by post-costal aspiration: The male is allowed to copulate for at least 12 minutes, a long uterine infusion pipette attached to 12 ml syringe (a-b) is used to aspirate semen from the vagina and uterus. C) The sample is often contaminated with blood from the female.

### Semen evaluation

Semen evaluation is performed using standard routine techniques as for other species. Semen parameters recorded should include color, volume, viscosity, sperm concentration, includes motility, and morphology. One of the major problems in evaluation of these parameters is the high variability between males and methods of collection (Table 2). In addition, evaluation of concentration, motility and morphology is often complicated due to the viscous nature of the ejaculate and may be a source of great variation when the ejaculate is not totally liquefied (Bravo et al., 1999)

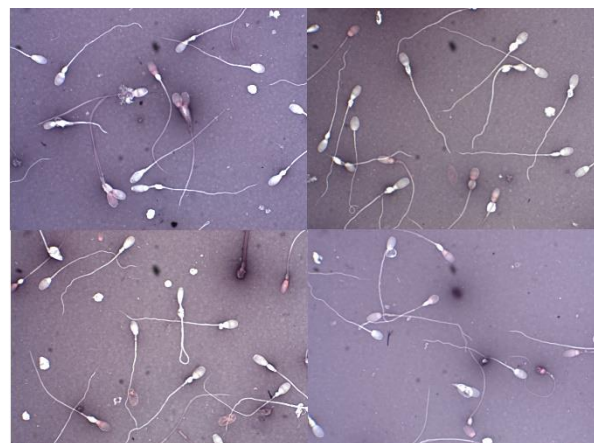The normal color of the ejaculate collected by EE or AV is generally gray to milky white depending on sperm concentration and amount of seminal plasma. Sperm concentration present a high variability. A non-negligible proportion of ejaculates (2 to 30%) obtained from normal males may be azoospermic (Baer and Hellemann, 1998; Giuliano et al., 2008).

Sperm motility is variable and dependent on the viscosity of the sample. In non-liquefied samples only oscillatory movement is observed and graded. Enzymatic treatments for liquefaction of the ejaculate have been proposed. The most promising of these treatments are incubation with papain or collagenase (Bravo et al., 2000; Giuliano et al., 2010; Giuliano, S., 2012; Morton et al., 2012; Kershaw-Young et al., 2013; Kershaw et al., 2017). There is a however a need for standardization of this treatment for routine breeding soundness evaluation.

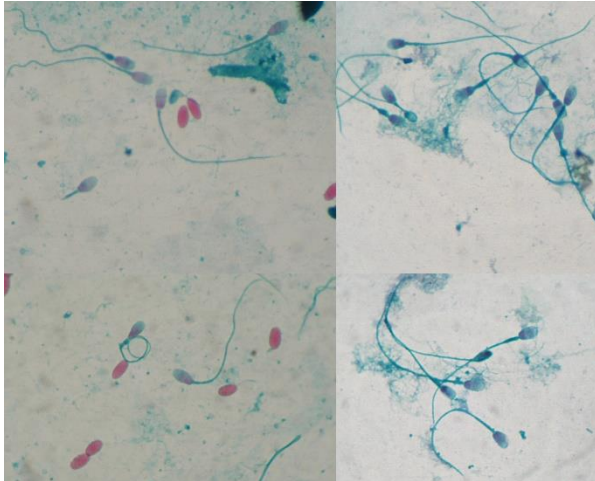
Routine sperm morphology evaluation is performed on stained smear using eosin-nigrosin (Figure 13), Spermac® (Figure 14) or unstained buffered formalin samples under phase contrast microscopy (Figure 15). The use of modified Giemsa stain (Diff Quick®) allows identification of round spermatid (spheroids) in cases of testicular degenerations (Figure 16). Sperm abnormalities found in SAC ejaculates are similar to those observed in other species. However, the significant of the type and rate of abnormalities in infertility has not been

investigation. Although many studies found greater than 70% normal morphology, lower rate of normal sperm is not unusual in sexually rested males.

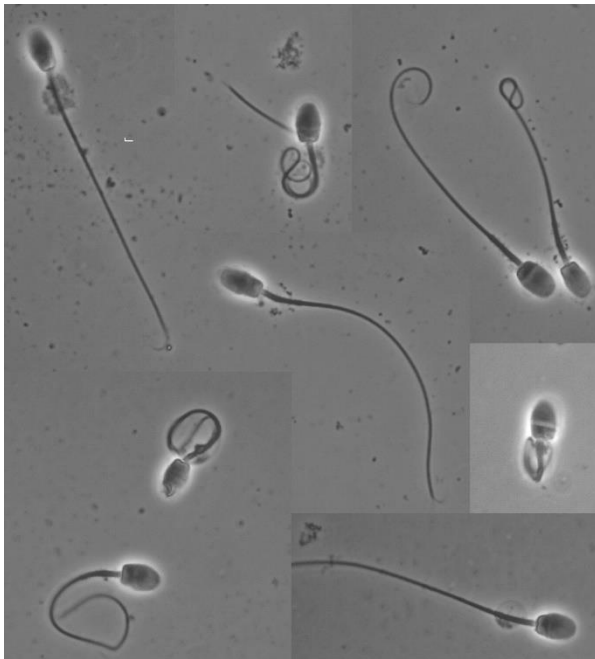
The extreme variability in ejaculate parameters may be due to length of copulation for AV collection, technical ability for EE, male variability, effect of season, and specific experimental climatic conditions (Ferré et al., 2015; Giuliano et al., 2008; Morton et al., 2010; Villanueva et al., 2018). In llamas, ejaculates obtained in the summer show higher proportion of abnormalities and lower concentration (Giuliano et al., 2008). Llamas exposed to an ambient temperature of 29°C for 4 weeks showed a significant decrease in ejaculate volume, sperm concentration, motility, and percentage of normal spermatozoa (Schwalm et al., 2008). The impaired spermatogenesis seen in heat stress is the results of degenerative changes in the seminiferous tubules (Schwalm et al., 2007). The effect of diet on sperm parameters is also suspected but has not been fully investigated (Juyena et al., 2013).



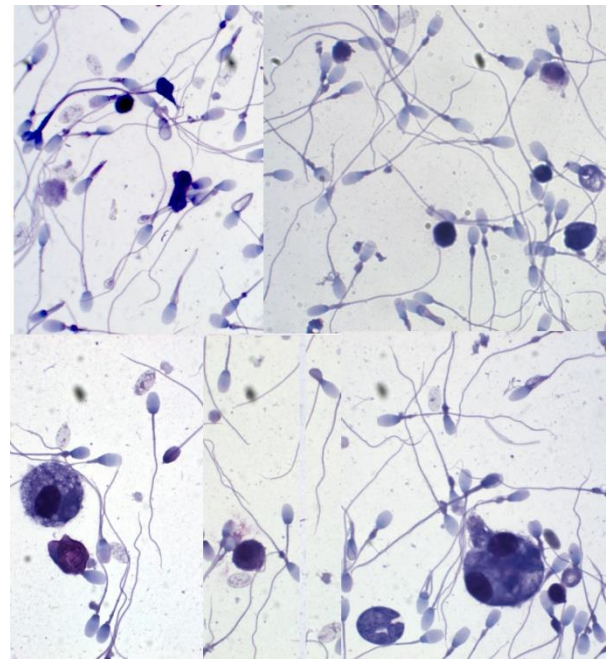
**Figure 13.** Eosin-nigrosin stain semen smear showing various abnormalities.



**Figure 14.** Spermac© stained semen smear.



**Figure 15.** Phase contrast evaluation after fixation with phosphate buffered saline



**Figure 16.** Modified Giemsa (Diff Quick®) stained semen smear. This technique is ideal for the detection of round spermatid (spheroids) which are common in cases of testicular degeneration

**Table 2.** Range values of ejaculate parameters collected by artificial vagina (AV) or electroejaculation (EE) in llamas and alpaca (Compiled from several studies)\*

Parameter	Alpacas		Llamas	
	AV	EE	AV	EE
Volume (ml)	0.3-3.8	0.25-1.75	0.5-4	0.2-9
Concentration ( $\times 10^6$ /ml)	46-250	10-60	10-150	3.12-632
Motility (%)	73	10-80	5-70	5-90
Viability (%)	55-85	50-80	5-80	2-84
Normal morphology (%)	70-85	50-80	20-80	10-80

\*Alpacas: (Alarcón B et al., 2012; Bravo et al., 1997a; Bravo et al., 1997b; Ferré et al., 2015; Flores et al., 2002; Giuliano et al., 2008; Morton et al., 2010; Villanueva et al., 2018)

\*Llamas: (Baer and Hellemann, 1998; Carretero et al., 2012; Fumuso et al., 2018; Giuliano et al., 2008; Lichtenwalner et al., 1996b; Schwalm et al., 2007)



### Advanced diagnostic techniques

Advanced diagnostic techniques for infertility or subfertility include testicular biopsy, trace mineral assay, endocrinology, and cytogenetics. Testicular biopsy is useful in cases of azoospermia, testicular hypoplasia, and neoplasia. The technique can help distinguish azoospermia of testicular (spermatogenic arrest) or non-testicular (occlusion of the epididymal ducts, ductus deferens, etc.) origin. Although fine needle aspiration may provide some information on spermatogenesis, sample evaluation and interpretation can be difficult. We recommend the use of trucut biopsy with a self-firing spring loaded biopsy needle (Tibary and Ruiz, 2018a). Trace mineral assay can help to identify deficiencies in zinc, copper, and selenium, all minerals which impact spermatogenesis and sperm maturation and function. Endocrinology testing is not very rewarding in most cases of subfertility. Low testosterone may provide some information on poor libido. Cytogenetic evaluation can identify chromosomal abnormalities in males which have poor semen quality, infertility, or pregnancy loss in bred females (Pearson et al., 2014).

Advanced methods of sperm evaluation have been studied but are not used routinely and could be useful in the future. These techniques include investigation of sperm chromatic integrity

using toluidine blue or flow cytometry (Carretero et al., 2012; Cheuquemán et al., 2013), and sperm morphometry (Buendía et al., 2002; Evangelista-Vargas et al., 2017). Electron microscopy may be considered in some cases of infertility (Pearson et al., 2014).

### RESULTS AND DISCUSSION

Male Infertility/subfertility cases fall generally into one of two categories: inability to complete a mating (Impotentia cuendi) or inability to achieve fertilization (Impotentia generandi). The most common reason for emergency presentation of a male are: Inability to breed, Preputial hemorrhage, sudden enlargement of the prepuce, sudden testicular enlargement and in young males persistent straining, posturing. Table 3 summarizes documented reproductive tract diagnosis in our clinic. Clinical incidence of various reproductive disorders in male alpacas presenting for routine breeding soundness examination (n= 202) or for infertility (n= 72) are presented in Table 4. Studies associating ejaculate quality parameters to fertility are scarce. In one study, pregnancy rate was higher in males with >50% motility, >70% viability, and >60% normal morphology (Bravo et al., 2016).

**Table 3.** Documented diseases of the reproductive organs in the male camelidae that have been diagnosed at the WSU Comparative Theriogenology service

Prepuce	Penis	Testis and epididymis	Accessory sex glands
Preputial edema (heat stress)	Persistent frenulum	Cryptorchidism	Prostate hypertrophy
Preputial obstruction	Short penis	Ectopic testicles	Prostate abscess
Preputial laceration	Prolapse penis	Hydrocele	Prostatic cyst
Preputial prolapse	Paraphymosis	Testicular degeneration	
Preputial necrosis	Balanitis	Testicular hypoplasia	
Posthitis	Ulcerations/Abrasions	Testicular neoplasia (seminoma)	
Preputial warts	Hair ring	Testicular cysts	
Phymosis	Penile warts	Orchitis	
	Urethral rupture	Epididymitis	
	Urethritis	Epididymal cyst	
	Urolithiasis	Epididymal segmental aplasia	

**Table 4.** Abnormalities of the reproductive systems in male alpacas submitted for routine breeding soundness examination (BSE, N=202) or infertility (N=71).

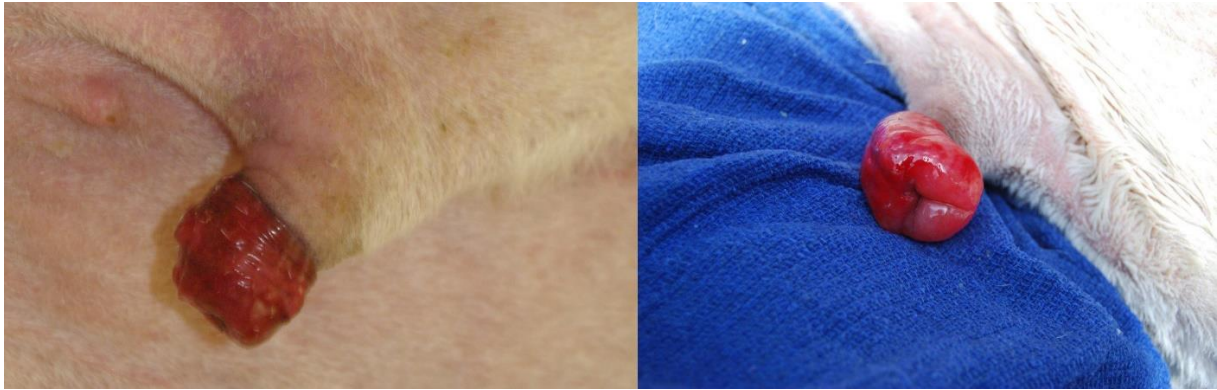Condition	Routine BSE		Infertile males	
	N	%	N	%
Rete testis cysts, bilateral	34	16.8	13	18.3
Rete testis cyst, unilateral	20	9.9	7	9.9
Testicular hypoplasia	17	8.4	1	1.4
Testicular degeneration	9	4.5	23	32.4
Persistent penile attachment	6	2.9	-	-
Cryptorchidism	4	1.9	-	-
Orchitis	2	0.9	4	5.6
Epididymal cysts	1	0.5	3	4.2
Preputial adhesions	-	-	4	5.4
Failure of erection	-	-	2	2.8

### Impotentia cuendi

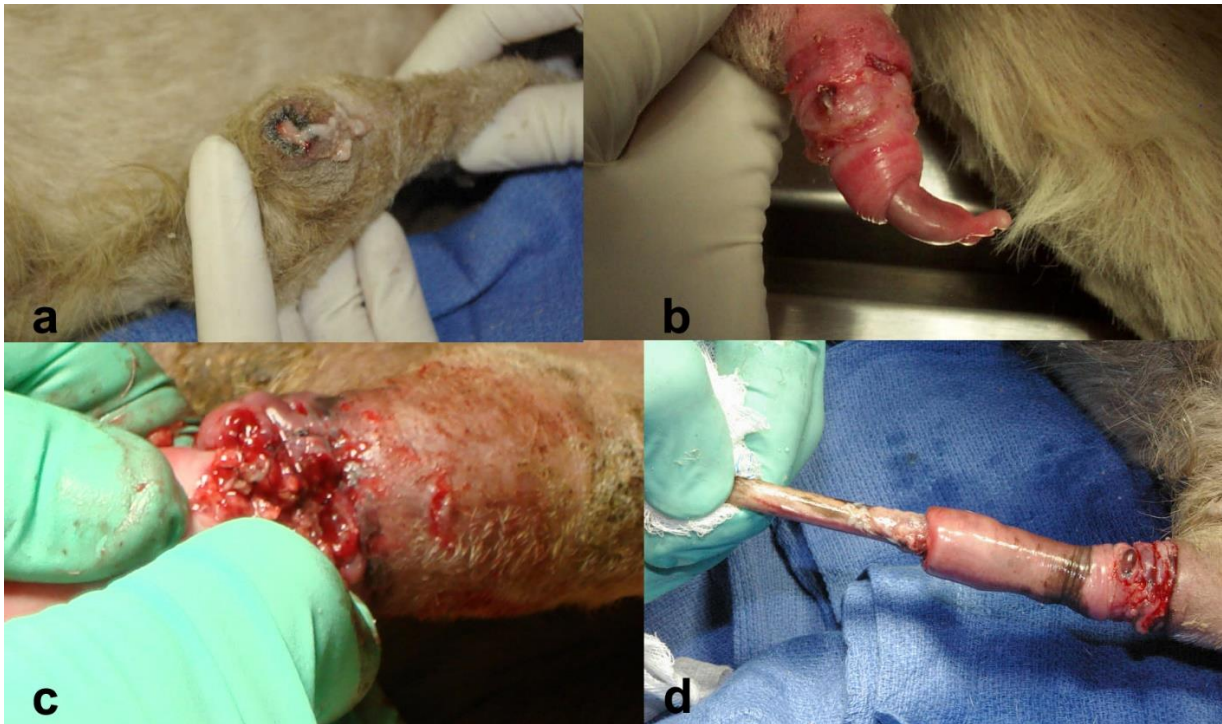Poor libido in male camelids is not well understood as far as the etiopathogenesis or predisposing factors. In young males, lack of sexual interest may be related to inexperience, shyness, or previous reprimands by handlers. In these cases, initiating of breeding in a familiar environment (i.e. on the farm, and not at the veterinary clinic), or observation of a mature male completing a breeding may increase the libido of the young male. Alternatively, hormone imbalance or systemic disease may affect sexual performance. Young males may require some patience to develop or encourage training of normal sexual behavior. In the adult male, or proven herd sire, any decrease in libido should be immediately investigated. The most common causes of decreased libido are systemic infections, musculoskeletal disorders including arthritis, or poor body condition. Additionally, heat stress or group housing with females may result in decreased sexual interest over time. Interestingly, in one case (llama), lack of libido was associated with megaesophagus.

Male camelids breed intrauterine within the female reproductive tract. Therefore, to complete a breeding, the penis must be free of its preputial attachments, of sufficient length, of normal shape to penetrate the cervix, and free of lesions. Inability to exteriorize the penis may indicate persistent frenulum or development of preputial-penile adhesions. These adhesions may be the consequences of preputial prolapse (Koziol et al., 2015; Pearson et al., 2014). Congenital short penis has been observed in 2 cases of infertility in our clinic. In

these cases, the male is unable to complete the intrauterine breeding, which can result in infertility both by failure of intrauterine deposition of semen and failure to induce ovulation. Penile lesions may include lacerations, hair rings, ulcerations, warts, or other lesions which may inhibit mating ability due to pain (Figure 17-20). Erection failure due to neurologic disease caused by meningeal worm infection.

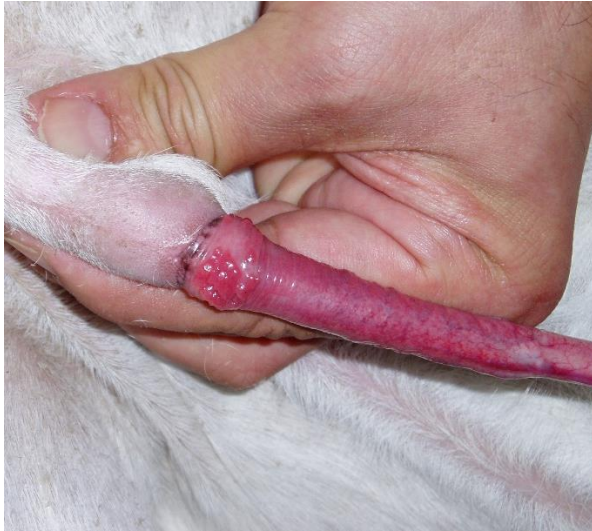

**Figure 17.** Preputial prolapse with excoriation (left) and edema (right).

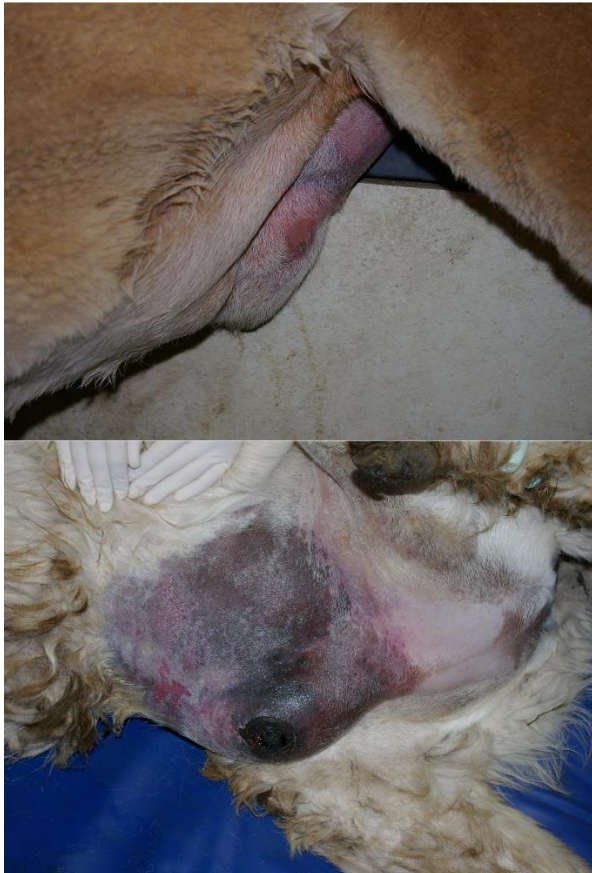

**Figure 18.** Preputial adhesions. a) purulent preputial discharge; a-c) preputial adhesions with various degrees of severity.





**Figure 19.** Balanoposthitis in a male alpaca with Impotentia cuendi due to pain.



**Figure 20.** Severe cases of balanoposthitis and tissue necrosis due to urine accumulation.

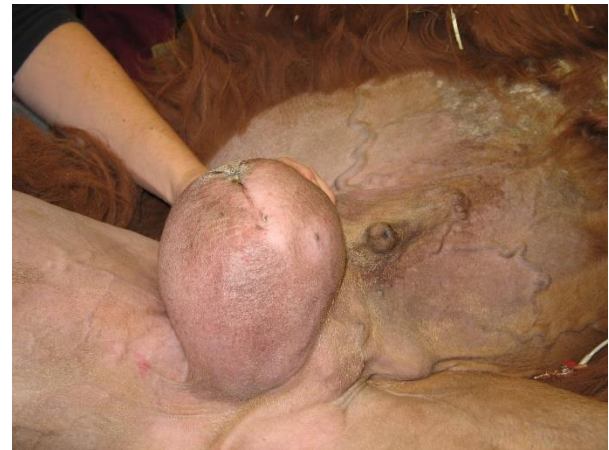#### Impotentia generandi

In our clinical cases, semen quality was below the set standards in 60.6% (n=43) of the males examined (teratozoospermia, n=34; poor motility, n=6; azoospermia, n=3). With the exception of 2 cases (one with asthenozoospermia and one with severe teratozoospermia), poor semen quality was associated with a testicular pathology. The predominant testicular

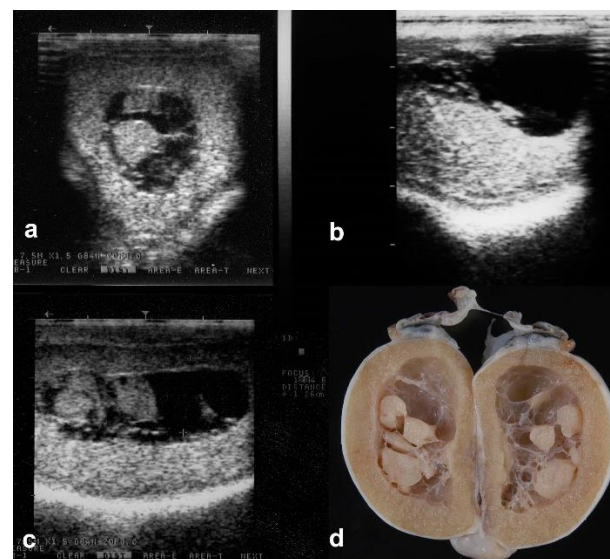
abnormalities were large rete testis cysts, testicular degeneration and atrophy, and testicular hypoplasia.

#### Rete testis cysts

Observations of rete testis cysts within the testes of male alpacas have been well documented but the etiopathogenesis and prevalence of these lesions remains poorly defined. Ultrasonographic examination was performed on 173 male alpacas presented for castration. Rete testis cysts were identified in 18.5% of animals; 40.6% of cases were bilateral (Figure 22). Cysts ranged in size from 4-45 mm (mean  $\pm$  SEM;  $13.3 \pm 1.3$ ) in length and 2-28 mm ( $6.5 \pm 0.8$ ) in width. Post-castration, cysts were aspirated; 44.4% of cysts contained immature spermatozoa. All cystic testes had evidence of spermatogenesis; however, disruption was observed in testes with large cysts. Examination of the epididymis of affected testes demonstrated that 20% were completely devoid of spermatozoa. Rete testis cysts can be a cause of subfertility or infertility and ultrasonographic examination of the testes should be included in the male breeding soundness examination as they are not palpable externally (Bott et al., 2010).



**Figure 21.** Inguinal abscess in a male llama.



**Figure 22.** Large rete testis cysts (a-c) with corresponding testis after castration (d).

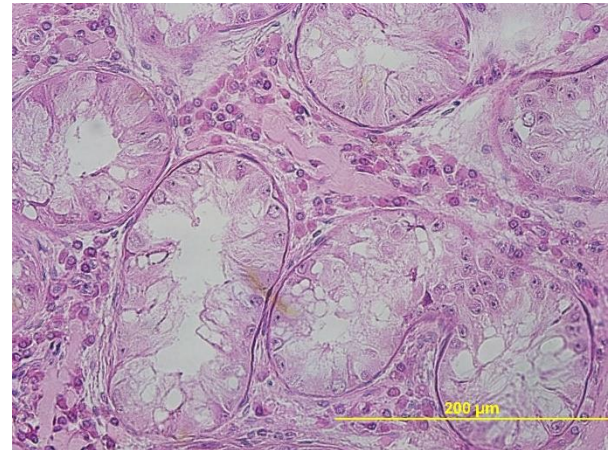


### Testicular degeneration

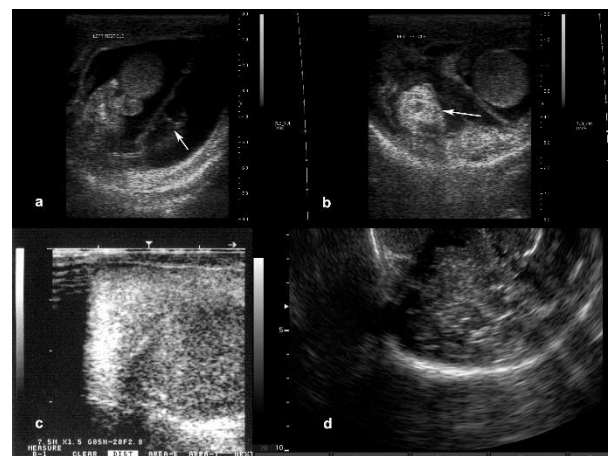
Testicular degeneration is hallmarked by disrupted spermatogenesis, decreased sperm output (oligozoospermia), increased abnormal morphology, or azoospermia. Histologically, seminiferous tubules may become smaller in diameter, with vacuolization and sloughing of the germinal epithelium (Figure 23). Inciting causes may include heat stress, high fever, trauma or inflammation of the scrotum or testes directly, chronic systemic illness, toxic insult, nutritional or hormone imbalance, or advanced age. On clinical examination, the testes are smaller than expected for the age of the male, and excess scrotal skin may be apparent, with an increased appearance of pendulous testes. Ultrasonographically, the testes may have small hyperechoic areas which suggest fibrosis. In many cases, the lesions are irreversible. However, in cases where azoospermia has not yet developed, it may be possible to mate males on a restricted schedule to fertile females and achieve a pregnancy.

### Other testicular conditions

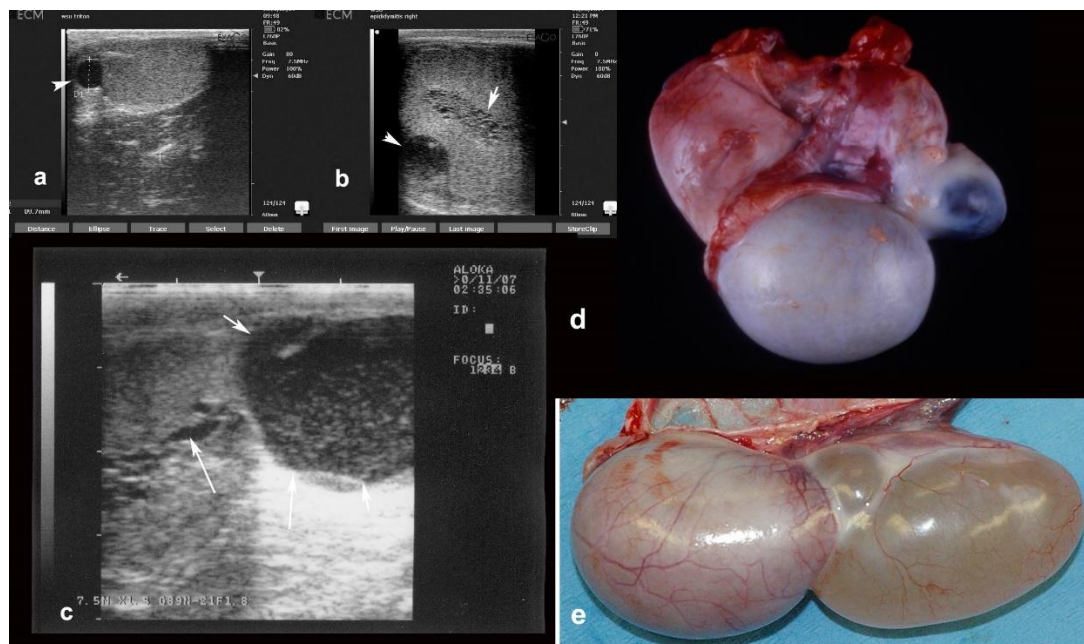
Several other conditions have been diagnosed in males with infertility including orchitis, epididymitis, epididymal cysts or segmental aplasia and testicular neoplasms (Figure 24-26). Causes of orchitis in camelids include brucellosis, *Strep. equi zooepidemicus*, filariosis (Aubry et al., 2000). Infection of the testes may also occur following trauma (fighting bites). The most common testicular neoplasia is seminoma.



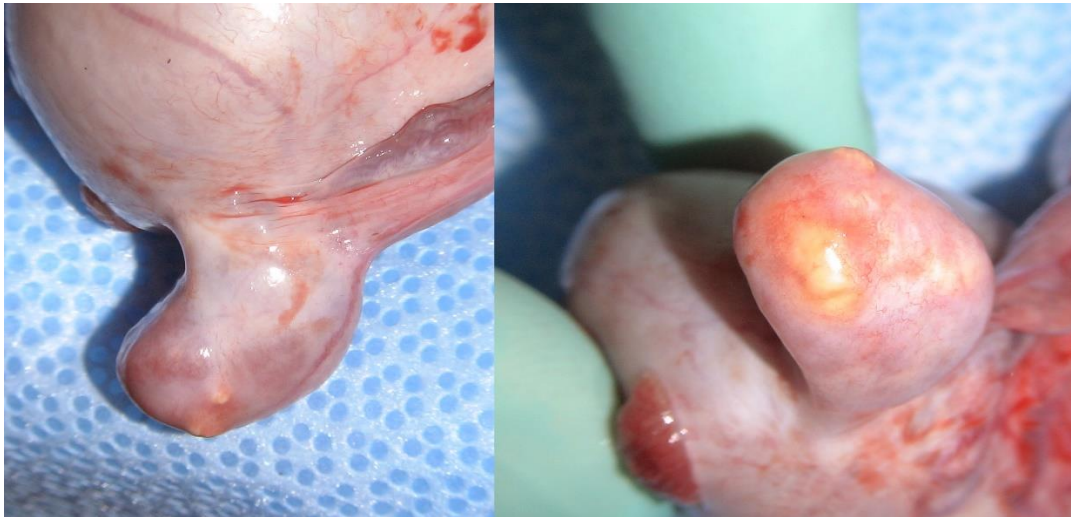**Figure 23.** Histology testicular degeneration.



**Figure 24.** Testicular abnormalities detected by ultrasonography in alpacas: a-b) testicular hemorrhage, b) testicular neoplasia.



**Figure 25.** Epididymal cyst: a) cauda epididymis cyst; b) head of the epididymis cysts and cystic rete testis; c) large cyst of the tail of the epididymis and cystic rete testis. d) and e) postcastration specimen from a and c, respectively.



**Figure 26.** Epididymal sperm granuloma.

### Azoospermia and oligozoospermia

Azoospermia may be of congenital or acquired pathogenesis. Congenital azoospermia is most often due to inherent defects in spermatogenesis or outflow obstruction via segmental aplasia along the epididymal ducts or ductus deferens. Testicular hypoplasia affects up to 10% of male camelids. The authors have observed a male in which spermatogenesis did not progress through meiosis. In animals with outflow obstruction, spermatogenesis may progress normally (as verified by testicular biopsy). However, ejaculation results only in emission of accessory sex gland secretions, with no testicular component.

Acquired azoospermia is usually of testicular origin. The most common inciting cause is testicular degeneration, typically due to heat stress, but may be reflective of other systemic processes. Azoospermia may be suspected based on infertility, failure to aspirate spermatozoa from a mated female, or failure to identify spermatozoa in a collection via EE. Confirmation is achieved by testicular biopsy, which may demonstrate varying degrees of testicular degeneration and/or fibrosis. As the spermatogenic cycle in camelids is thought to be approximately 60 days, sexual rest for at least 2 months may demonstrate resumption of spermatogenesis if the insult was transient; however, in many cases the effects are permanent. Azoospermia may also be observed in males with large rete testis cysts which obliterate the entire normal testicular parenchyma.

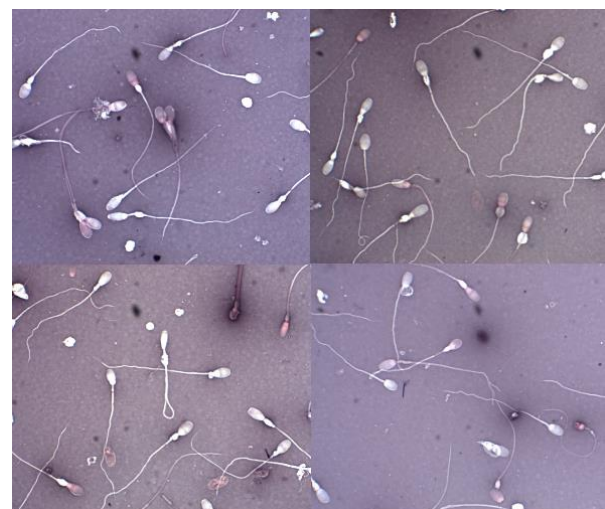It is important to note that seminal plasma alkaline phosphatase is not a marker of contribution of the testis and epididymis ejaculation in alpacas as in dogs and horses (Pearson et al., 2013). Therefore, it cannot be used to differentiate between azoospermia due blockage vs. lack of spermatogenesis, testicular biopsy remains the gold standard for diagnosis.

### Teratozoospermia

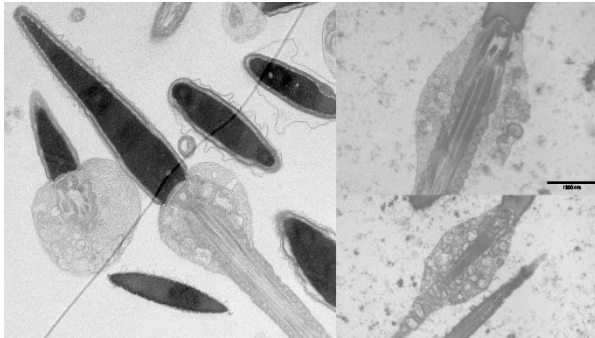High proportion of morphologically abnormal spermatozoa in the ejaculate is classified as teratozoospermia and may reflect inherent defects in spermatogenesis or epididymal maturation (Figure 27). In other species, a high percentage of morphologically normal spermatozoa are required for a male to be classified as a satisfactory potential breeder (i.e., 70% in bulls). However, male camelids may demonstrate high

percentages of abnormal morphology. Studies have demonstrated successful herd sires which only demonstrated at times 50% morphologically normal spermatozoa. Many other non-breeding males which were submitted to the authors' practice had less than 30% normal morphology. As stated above, SAC have highly variable sperm morphology. As the BSE is not standardized for camelid species, and because the proportion of males submitted for BSE is low (compared to the number of breeding males in use), much research is needed to determine the parameters of an ejaculate which are required for maximal fertility. Teratozoospermia is associated with heat stress.

Evaluation of teratozoospermia may require use of several staining methodologies. The traditional eosin-nigrosin stain for morphology may help to identify the specific morphologic abnormalities which are present. Specialized stains such as Spermac® are used to identify acrosome integrity. In one case, the authors used electron microscopy to diagnose abnormalities of the spermatozoa ultrastructure at the level of the mitochondrial sheath (Figure 28).



**Figure 27.** Semen smears from an infertile male with normal size testicles and severe teratozoospermia with a particular defect of the mitochondrial sheath.



**Figure 28.** Electron microscopy of sperm from male in figure 27.

For diagnosed cases of teratozoospermia, the prognosis is guarded. A thorough evaluation of the nutrition, trace minerals, and general health status of the animal is warranted. Testicular ultrasonography and biopsy may provide diagnostic information. In some cases, despite at least 60 days sexual rest and correction of all identified management issues, the etiopathogenesis of the condition remains undiagnosed.

## CONCLUSION

Loss of breeding function of a herd sire can have severe effects on a herd, not only in terms of crias produced but also time, labor, and finances. Owners should be educated of the importance of male BSE prior to the breeding season. Several congenital problems (testicular hypoplasia, cryptorchidism, ectopic testis) can be identified prior to breeding and males removed from the herd. Furthermore, early detection of lesions may save the reproductive life of the male if addressed immediately. Breeding soundness evaluation methodology and standards should be developed in order to be able to have a basis for comparison amongst studies. The ability to induce ovulation in a reliable fashion ("seminal plasma potency") is an aspect of SAC male infertility that merit further investigation.

## REFERENCES

- Abraham MC, Puhakka J, Ruete A, Al-Essawe EM, Verdier Kd, Morrell JM, Båge R. Testicular length as an indicator of the onset of sperm production in alpacas under Swedish conditions. *Acta Veterinaria Scandinavica*. 2016; 58.
- Adams GP, Ratto MH, Silva ME, Carrasco RA. Ovulation-inducing factor (OIF/NGF) in seminal plasma: a review and update. *Reprod Domest Anim*. 2016; 51: 4-17.
- Alarcón BV, García VW, Bravo PW. Artificial insemination of alpacas with semen collected by vaginal aspiration and by artificial vagina. *Revista de Investigaciones Veterinarias del Perú (RIVEP)*. 2012; 23: 58-64.
- Apichela SA, Argañaraz ME, Giuliano S, Zampini R, Carretero I, Miragaya M, Miceli DC. Llama oviductal sperm reservoirs: involvement of bulbourethral glands. *Andrologia*. 2014; 46: 290-295.
- Aubry P, Swor TM, Löhr CV, Tibary A, Barrington GM. Septic orchitis in an alpaca. *Canadian Veterinary Journal*. 2000; 41: 704-706.
- Baer Lv, Hellemann C. Semen characteristics in the llama (*Lama glama*). *Archivos de Medicina Veterinaria*. 1998; 30: 171-176.
- Bott I, Pearson LK, Rodriguez JS, Sandoval S, Kasimanickam RK, Sumar J, Tibary A. Prevalence and Pathologic Features of Rete Testis Cysts in Alpacas (*Vicugna pacos*). *Clinical Theriogenology*. 2010; 2: 395.
- Bravo P. Male reproduction. In: *The Reproductive Process of South American Camelids*. Bravo Publishing. 2002; 49-64.
- Bravo PW. Chapter 15: Reproductive anatomy and physiology in the male, In: Cebra C, Anderson DE, Tibary A, Van Sau R, Johnson LW (Eds.). *Llama and Alpaca Care: Medicine, Surgery, Reproduction, Nutrition, and Herd Health*, Elsevier, Ames, Iowa. 2014; 150-161.
- Bravo PW, Ccallo M, Garnica J. The effect of enzymes on semen viscosity in llamas and alpacas. *Small Ruminant Res*. 2000; 38: 91-95.
- Bravo PW, Flores D, Ordoñez C. Effect of repeated collection on semen characteristics of alpacas. *Biology of Reproduction*. 1997a; 57: 520-524.
- Bravo PW, Flores U, Garnica J, Ordoñez C. Collection of semen and artificial insemination of alpacas. *Theriogenology*. 1997b; 47: 619-626.
- Bravo PW, Pacheco C, Quispe G, Vilcapaza L, Ordoñez C. Degelification of alpaca semen and the effect of dilution rates on artificial insemination outcome. *Archives of Andrology*. 1999; 43: 239-246.
- Bravo PW, Ugarte M, Alarcón BV. Semen quality and fertility of the male alpaca, In: Juhasz J, Nagy P, Skidmore J, Malo C. (Eds.) *The ICAR Satellite Meeting On Camelid Reproduction*, University of Francois-Rabelia, Faculty of Science and TechnologyTours, France. 2016; 74-78.
- Buendía P, Soler C, Paolicchi F, Gago G, Urquieta B, Pérez-Sánchez F, Bustos-Obregón E. Morphometric characterization and classification of alpaca sperm heads using the Sperm-Class Analyzer® computer-assisted system. *Theriogenology*. 2002; 57: 1207-1218.
- Campbell AJ, Tibary A. Infertility of female and male camelids. *Clinical Theriogenology*. 2017; 9: 311-319.
- Carretero MI, Lombardo D, Arraztoa CC, Giuliano SM, Gambarotta MC, Neild DM. Evaluation of DNA fragmentation in llama (*Lama glama*) sperm using the sperm chromatin dispersion test. *Animal Reproduction Science*. 2012; 131: 63-71.
- Cheuquemán C, Merino O, Giojalas L, Baer Av, Sánchez R, Risopatrón J. Assessment of sperm function parameters and DNA fragmentation in ejaculated alpaca sperm (*Lama pacos*) by flow cytometry. *Reprod Domest Anim*. 2013; 48: 447-453.
- Condorena AN, Velasco NJ. A comparison of two mating systems in the alpaca. *Memoria, Asociacion Latinoamericana de Produccion Animal*. 1978; 13: 159-160.
- Delhon G, Lawzewitsch Iv. Ductus epididymidis compartments and morphology of epididymal spermatozoa in llamas. *Anatomia Histologia Embryologia*. 1994; 23: 217-225.
- Delhon GA, Lawzewitsch Iv. Reproduction in the male llama (*Lama glama*), a South American camelid. I. Spermatogenesis and organization of the intertubular space of the mature testis. *Acta Anatomica*. 1987; 129: 59-66.
- El Zawam A. Establishment of spermatogenesis following testicular tissue ectopic xenografting in alpaca, Department of Veterinary Clinical Science, College of Veterinary Medicine, Washington State University, Pullman, WA. 2013
- Evangelista-Vargas D, Evangelista-Vargas S, Valdivia M, Santiani A. Assessment of spermatozoa in fertile alpaca



- (*Vicugna pacos*) males: study of sperm head morphometry using a nonautomated digital method and sperm morphology based on strict criteria. *Reprod Domest Anim.* 2017; 52: 312-318.
- Ferré LB, Malik G, Aller JF, Alberio RH, Fresno C, Kjelland ME. Llama (*Lama glama*) semen collection via thermo-electric artificial vagina: effect of seasonality and collection interval on ejaculate characteristics. *Small Ruminant Res.* 2015; 133: 140-147.
  - Flores P, García-Huidobro J, Muñoz C, Bustos-Obregón E, Urquieta B. Alpaca semen characteristics previous to a mating period. *Animal Reproduction Science.* 2002; 72: 259-266.
  - Fumuso FG, Giuliano SM, Chaves MG, Neild DM, Miragaya MH, Gambarotta MC, Carretero ML. Seminal plasma affects the survival rate and motility pattern of raw llama spermatozoa. *Animal Reproduction Science.* 2018; 192: 99-106.
  - Giuliano S. Extracción y evaluación de semen de camélidos sudamericano. *Spermova.* 2012; 2:6-9.
  - Giuliano S, Carretero M, Gambarotta M, Neild D, Trasorras V, Pinto M, Miragaya M. Improvement of llama (*Lama glama*) seminal characteristics using collagenase. *Animal Reproduction Science.* 2010; 118: 98-102.
  - Giuliano S, Director A, Gambarotta M, Trasorras V, Miragaya M. Collection method, season and individual variation on seminal characteristics in the llama (*Lama glama*). *Animal Reproduction Science.* 2008; 104: 359-369.
  - Huanca T, Mamani RH, Naveros ML, Pacheco JI, Condori N. Variación individual y estacional de las características seminales en la alpaca (*Vicugna pacos*). *Spermova.* 2011; 1: 98-100.
  - Juyena NS, Vencato J, Pasini G, Vazzana I, Stelletta C. Alpaca semen quality in relation to different diets. *Reproduction, Fertility and Development.* 2013; 25: 683-690.
  - Kershaw-Young CM, Druart X, Vaughan J, Maxwell WMC.  $\beta$ -Nerve growth factor is a major component of alpaca seminal plasma and induces ovulation in female alpacas. *Reproduction, Fertility and Development.* 2012; 24: 1093-1097.
  - Kershaw-Young CM, Stuart C, Evans G, Maxwell WMC. The effect of glycosaminoglycan enzymes and proteases on the viscosity of alpaca seminal plasma and sperm function. *Animal Reproduction Science.* 2013; 138: 261-267.
  - Kershaw CM, Evans G, Rodney R, Maxwell WMC. Papain and its inhibitor E-64 reduce camelid semen viscosity without impairing sperm function and improve post-thaw motility rates. *Reproduction, Fertility and Development.* 2017; 29: 1107-1114.
  - Koziol JH, Edmondson MA, Wolfe DF, Bayne JE. Successful resolution of a preputial prolapse in an alpaca using medical therapy. *Canadian Veterinary Journal.* 2015; 56: 753-755.
  - Lichtenwalner AB, Woods GL, Weber JA. Ejaculatory pattern of llamas during copulation. *Theriogenology.* 1996a; 46: 285-291.
  - Lichtenwalner AB, Woods GL, Weber JA. Seminal collection, seminal characteristics and pattern of ejaculation in llamas. *Theriogenology.* 1996b; 46: 293-305.
  - Mendoza TG, Castro A, Lupidio M, Domínguez M, Gómez S, Ghezzi M. Macroscopic and microscopic characterization of the reproductive glands of the male llama (*Lama glama*). *Revista de Investigaciones Veterinarias del Perú (RIVEP).* 2012; 23: 27-42.
  - Muchotrigo D, Trelles X, Olazábal J, Choez K, Evangelista S, Santiani A. Probabilidad de obtención de semen de alpaca utilizando vagina artificial en lotes de machos sin entrenamiento. *Spermova.* 2013; 3: 95-96.
  - Morton KM, Gibb Z, Leahy T, Maxwell WMC. Effect of enzyme treatment and mechanical removal of alpaca (*Vicugna pacos*) seminal plasma on sperm functional integrity. *Journal of Camelid Science.* 2012; 5: 62-81.
  - Morton KM, Thomson PC, Bailey K, Evans G, Maxwell WMC. Quality parameters for alpaca (*Vicugna pacos*) semen are affected by semen collection procedure. *Reprod Domest Anim.* 2010; 45: 637-643.
  - Oscanoa MA, Leyva VV, García VW, Cruz MRGdl, Alarcón BV. Effect of the exogenous testosterone on the penis-prepuccial adherences and fiber production in Huacaya alpacas. *Revista de Investigaciones Veterinarias del Perú (RIVEP).* 2017; 28: 327-336.
  - Pacheco Curie JI. Methods of semen collection in South American camelids. *REDVET.* 2008; 9: 040806.
  - Pearson LK, Campbell AJ, Sandoval S, Tibary A. Effects of Vasectomy on Seminal Plasma Alkaline Phosphatase in Male Alpacas (*Vicugna pacos*). *Reprod Domest Anim.* 2013; 48: 995-1000.
  - Pearson LK, Rodríguez JS, Tibary A. Chapter 19 - Infertility and Subfertility in the Male, In: Cebra, C., Anderson, D.E., Tibary, A., Saun, R.J.V., Johnson, L.W. (Eds.), *Llama and Alpaca Care*, W.B. Saunders, St. Louis. 2014; 194-216.
  - Picha Y, Sandoval S, Pearson LK, Elzawam A, Alkar A, Tibary A. Evaluation of stress response to electroejaculation in anesthetized alpacas (*Vicugna pacos*). *Clinical Theriogenology.* 2011; 3: 380.
  - Sánchez AE, Correa JE. Ultrasonographic description of accessory sex glands in the male llama. *Archivos de Medicina Veterinaria.* 1995; 27: 81-86.
  - Schwalm A, Erhardt G, Gerken M, Moors E, Gaulty M. Influence of heat stress on thermoregulation and fertility in shorn and unshorn male llamas (*Lama glama*). *Tierärztliche Praxis. Ausgabe G, Grosstiere/Nutztiere.* 2008; 36: 324-328.
  - Schwalm A, Gaulty M, Erhardt G, Bergmann M. Changes in testicular histology and sperm quality in llamas (*Lama glama*), following exposure to high ambient temperature. *Theriogenology.* 2007; 67: 1316-1323.
  - Sumar J. Studies on Reproductive Pathology in Alpacas. MS Thesis. Dept. Obstet and Gynaec., College of Vet Med, Swedish, Univ. of Agric Sci., Uppsala. 1983.
  - Sumar J. Defectos congénitos y hereditarios en la alpaca teratología. Edición auspiciada por el Consejo Nacional de Ciencia y Tecnología, Lima, Peru. 1989.
  - Tibary A, Campbell AJ. Clinical incidence of various reproductive disorders in male alpacas (*V. pacos*), In: Juhasz J, Nagy P, Skidmore J, Malo C (Eds.). *The ICAR Satellite Meeting On Camelid Reproduction*, University of Francois-Rabelia, Faculty of Science and TechnologyTours, France. 2016; 106-109.
  - Tibary A, Pearson LK, Anouassi A. Applied andrology in camelids, CABI, Wallingford. 2014; 418-449.
  - Tibary A, Picha Y, Pearson LK. Congenital and possibly hereditary causes of infertility in camelids. 2011; 324-326.
  - Tibary A, Ruiz A. Testicular biopsy, methodology and interpretation, Symposium "Female and male infertility diagnosis in camelids, Centro Experimental La Raya, UNSAAC, Cusco, Peru. 2018a.
  - Tibary A, Ruiz A. Testicular ultrasonography, methodology and interpretation, Symposium "Female and male infertility diagnosis in camelids, Centro Experimental La Raya, UNSAAC, Cusco, Peru. 2018b.

- Tibary A, Vaughan J. Reproductive physiology and infertility in male South American camelids: A review and clinical observations. *Small Ruminant Res.* 2006; 61: 283-298.
- Vaughan JL, Lonsdale RA, Jackson G, Ryan DP. Congenital caudal vertebral malformations in the alpaca (*Lama pacos*). *Australian Veterinary Journal.* 2000; 78: 412-415.
- Villanueva MJC, Huanca MWF, Hilari OF, Uchuari PM, Rodríguez GF, Huanca LW. Seasonal effect on the seminal characteristics of alpacas (*Vicugna pacos*) raised at sea level. *Revista de Investigaciones Veterinarias del Perú (RIVEP).* 2018; 29: 559-564.
-